



**PRESENTING CLINICAL SIGNS**

History: Grade III/VI murmur. Coughing, gagging.

**DATE**

2/20/23

**ECHOCARDIOGRAPHIC FINDINGS**

2D, M-mode, and Doppler study.

**PERFORMED BY:**

Shari Reffi, CVT

**INTERPRETED BY**

Keith Blass, DVM,  
MS, DACVIM  
(Cardiology)

Left atrial size is normal. The mitral valve leaflets are mildly thickened, there is Doppler evidence of mitral regurgitation present. Left ventricular dimensions are normal. Left ventricular systolic function is hyperdynamic. The aorta and aortic valve are normal. Right atrial and right ventricular dimensions are normal. The tricuspid valve leaflets are mildly thickened, and there is Doppler evidence of tricuspid regurgitation present. TR velocity does not suggest the presence of pulmonary hypertension. The pulmonary artery and pulmonary are normal. No shunting lesions are visualized. No pericardial effusion or cardiac masses are seen.

**PATIENT**

Robby Kachele

LA - 28.1 mm  
LVIDd - 27.1 mm  
LVIDs - 14.9 mm  
FS - 45%  
RA - 19.8 mm  
LVOT - 1.23 m/s  
RVOT - 0.99 m/s  
TR - 2.75 m/s

**SPECIES**

Canine

**BREED**

Dachshund

**ASSESSMENT/RECOMMENDATIONS**

Degenerative mitral and tricuspid valve disease

This examination demonstrates regurgitation of blood across Robby's mitral and tricuspid valves resulting from degenerative valve disease. The hemodynamic effects of each of the regurgitations appear to be mild, as Robby does not have secondary dilation of any his cardiac chambers. As such, Robby's valvular diseases appear to be well-compensated, and his coughing/gagging is unlikely to be cardiogenic in origin.

No therapy is recommended at this stage of Robby's valvular diseases.

**SEX**

Thoracic radiographs are recommended to further evaluate Robby's cough.

**MN**

A recheck echocardiogram is recommended in 6 months to monitor for disease progression.

**AGE**

13 y

**WEIGHT**

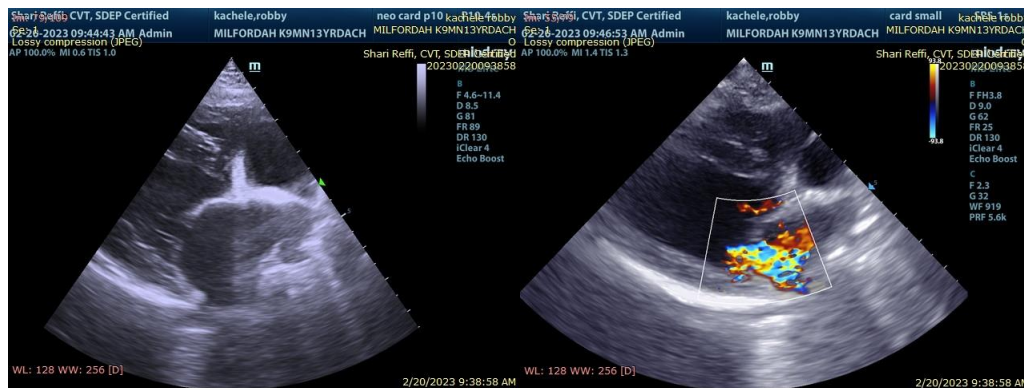
17 lb

**HOSPITAL NAME**

Milford AH

**REFERRING VET**

Dr. Grasso



The information and recommendations provided are based on the images presented by the referring veterinarian. No evaluation can be communicated regarding pathology that was not



visible in the image/video clips provided.

**DATE** Thank you for this referral. If the clinical or image interpretation does not parallel your findings or if I can be of any further assistance please contact me.

2/20/23

**PERFORMED BY:** Keith Blass, DVM, MS, DACVIM (Cardiology)  
KeithBlass@gmail.com  
631-804-5754

Shari Reffi, CVT

**INTERPRETED BY**

Keith Blass, DVM,  
MS, DACVIM  
(Cardiology)

**PATIENT**

Robby Kachele

**SPECIES**

Canine

**BREED**

Dachshund

**SEX**

MN

**AGE**

13 y

**WEIGHT**

17 lb

**HOSPITAL NAME**

Milford AH

**REFERRING VET**

Dr. Grasso